

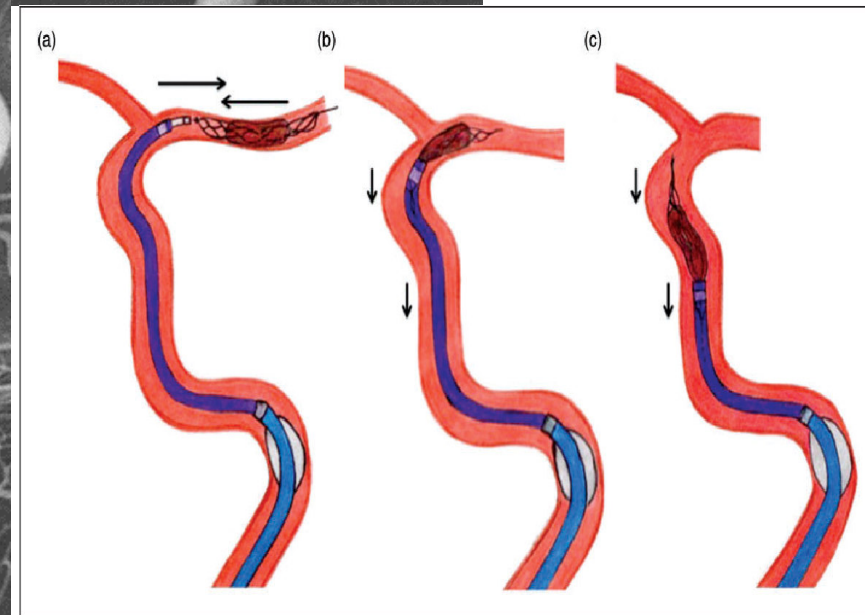
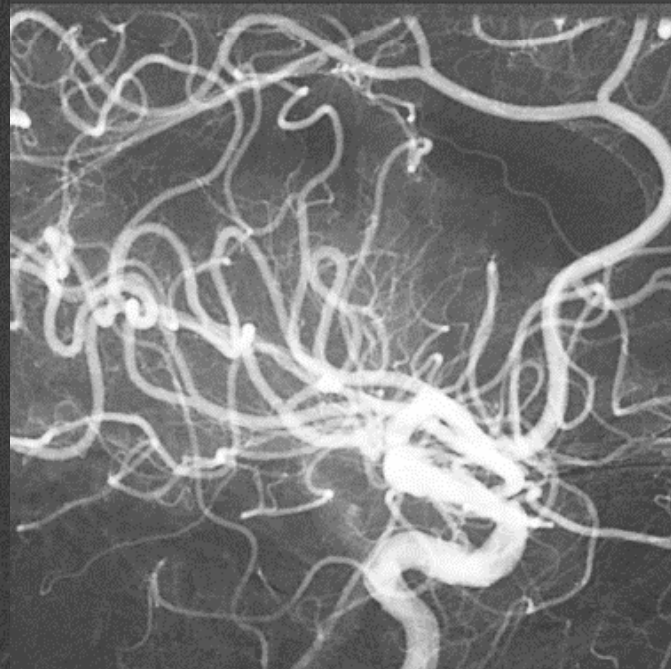
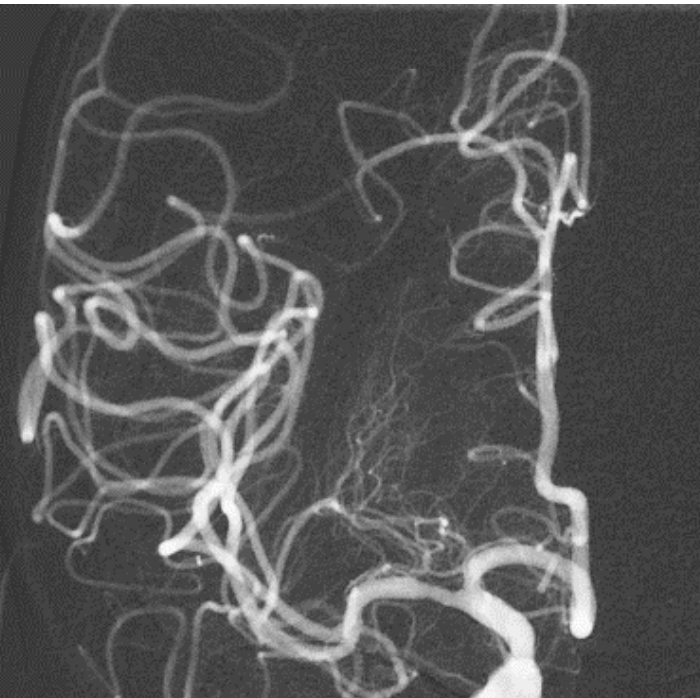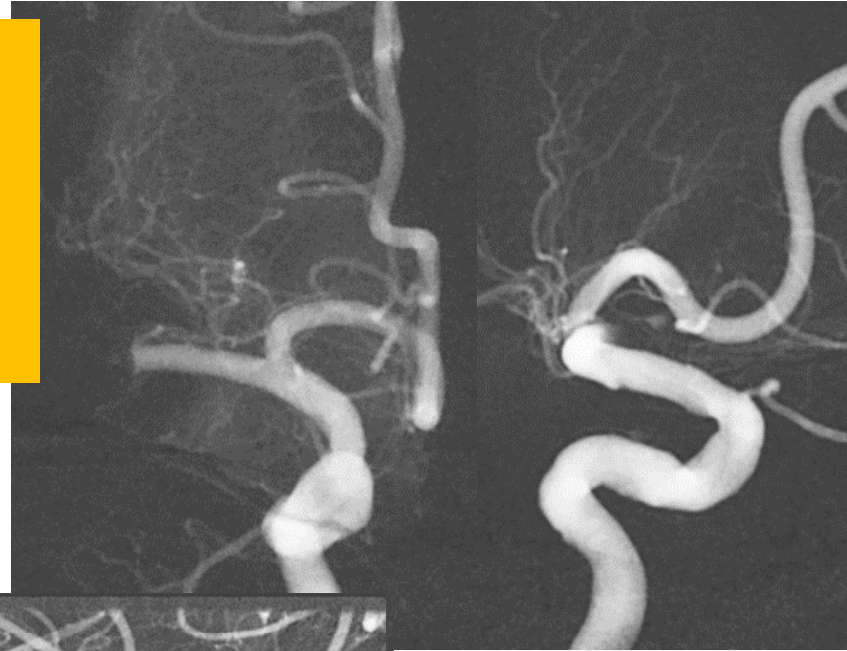
Ictus isquémico agudo

Oclusión de la arteria cerebral media derecha

Nihss 18 .

Trombectomía mecánica con stentriever-aspiración distal.

1 pase con recanalización completa.



"SOLUMBRA" TECHNIQUE

"ARTS" TECHNIQUE

"SAVE" TECHNIQUE

